

The efficacy and safety of an office-based polypectomy with a vacuum-powered microdebrider

Eng Cern Gan, MBBS, MRCS (Edin), MMED (ORL), Al-Rahim R. Habib, BSc, Iain Hathorn, MBChB, FRCS (ORL-HNS) and Amin R. Javer, BSc, MD, FRCSC, FARS

Background: The waiting time for functional endoscopic sinus surgery (FESS) in patients with chronic rhinosinusitis with nasal polyposis (CRSwNP) in the Canadian public healthcare system can be lengthy. Many such patients have significant nasal obstruction resulting in a poor quality of life. A simple and safe office-based polypectomy device to debulk nasal polyps allows immediate alleviation of nasal obstruction and better access for topical medications. The aim of this study is to assess the efficacy, safety, and patient tolerability of a vacuum-powered microdebrider in the outpatient clinic setting.

Methods: The clinical charts of patients with CRSwNP who underwent office polypectomy with a vacuum-powered microdebrider between May 2012 and February 2013 were retrospectively reviewed. These patients were either awaiting surgery or had recurrent polyposis postsurgery that was amenable to office polypectomy. Previously completed procedural and clinical outcomes questionnaires by the patients and surgeon were analyzed.

Results: Sixty-eight patients underwent office polypectomy in this case series. Fifty-nine procedures (87%) were

successfully completed. Failed complete polyp resections were due to fibrous polyps ($n = 7$; 10%), device failure ($n = 1$; 1.5%), and obstruction from a deviated nasal septum ($n = 1$; 1.5%). There was a 43% improvement in nasal obstruction score and significant reduction in polyp grade postpolypectomy. Majority of patients ($n = 66$; 97%) reported a comfort level of "fair" to "excellent." Bleeding was "light" in 61 cases (90%). There were no complications encountered.

Conclusion: The vacuum-powered microdebrider is a safe, effective, and well-tolerated instrument to resect nonfibrous nasal polyps in the outpatient setting. © 2013 ARS-AAOA, LLC.

Key Words:

nasal polyps; outpatient clinic; equipment; safety; treatment efficacy

How to Cite this Article:

Gan EC, Habib A-RR, Hathorn I, Javer AR. The efficacy and safety of an office-based polypectomy with a vacuum-powered microdebrider. *Int Forum Allergy Rhinol.* 2013;3:890-895.

Chronic rhinosinusitis (CRS) refers to inflammation of the nasal cavity and paranasal sinuses with symptoms lasting more than 12 weeks.¹ It is a common disorder, affecting up to 5% of the adult population in Canada.² Phenotypically, CRS is divided into 2 groups: CRS without nasal polyposis (CRSsNP) and CRS with nasal polyposis (CRSwNP). CRSwNP accounts for 20% to 33% of patients with CRS and has a higher association with asthma,

aspirin-exacerbated respiratory disease (AERD), and allergic fungal rhinosinusitis (AFRS) compared to CRSsNP.³ The health burden of with CRSwNP patients has also been shown to be greater than that of CRSsNP patients.⁴ It has been estimated that up to 50% of CRSwNP patients may eventually require surgical intervention.⁵

As the waiting time for functional endoscopic sinus surgery (FESS) in the Canadian public healthcare system can be lengthy, office polypectomy has become a viable option to provide a nasal airway for those suffering from severe nasal obstruction, or for patients unfit for general anesthesia. Creating space in the nasal cavity will also allow for better access and distribution of topical medications into the paranasal sinuses. Traditionally, office polypectomy was performed with headlight illumination, using snares and/or straight grasping instruments under local topical anesthesia and vasoconstriction.^{6,7} This often led to mucosal stripping, increased bleeding resulting

Division of Otolaryngology, University of British Columbia, St. Paul's Sinus Centre, Vancouver, British Columbia, Canada

Correspondence to: Eng Cern Gan, MBBS, MRCS (Edin), MMED (ORL), St. Paul's Sinus Centre, 1081 Burrard Street, Vancouver, BC, V6Z 1Y6, Canada; e-mail: engcern@gmail.com

Potential conflict of interest: Dr. Javer reports other from Laurimed LLC, outside the submitted work; and Devices were supplied free-of-charge for the purpose of this research study.

Received: 11 March 2013; Revised: 29 May 2013; Accepted: 6 June 2013
DOI: 10.1002/alr.21198

View this article online at wileyonlinelibrary.com.

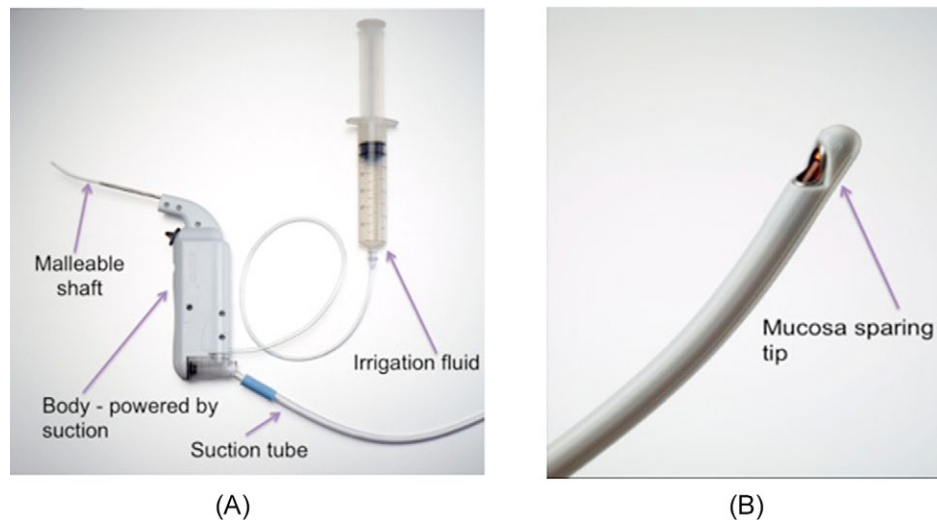


FIGURE 1. (A) The vacuum-powered microdebrider. (B) The mucosal sparing microdebrider blade.

in an impaired surgical visual field, and an unsatisfactory result.⁷ The introduction of powered endonasal instrumentation and nasal endoscopes resulted in an improvement in surgical field visualization, finer dissection, and less tissue damage during polypectomy.⁷ A powered endonasal instrument is a motor-driven device with a sharp rotating cutting blade coupled with continuous suction.⁸ The electric-powered microdebriders have high oscillating blade speeds with sharp cutting capabilities. However, the setup of the instrument can be cumbersome and laborious. In addition, an electric-powered microdebrider has to be sterilized after each use, which limits the number of procedures that can be performed in a clinic session. With the introduction of a new, single-use, disposable vacuum-powered microdebrider (PolypVac; Laurimed LLC, Redwood City, CA), the issues faced with the electric-powered microdebrider may become moot. We feel that the vacuum-powered microdebrider is comparable to an electric-powered microdebrider in terms of efficacy and safety, but in addition it does not require an assistant, has an easier setup, and enables multiple polypectomies to be scheduled in a single clinic session with no downtime for sterilization of the equipment. The improved efficiency of the vacuum-powered microdebrider allows patients requiring polypectomies to have the procedure performed on the day of their clinic visit. Same-day treatment is particularly beneficial for patients visiting from a distant location, patients with severe nasal obstruction, and patients with severe disease requiring polyp debulking to allow better access of medication into the sinus cavities. In this study, we report the safety and efficacy of a novel vacuum-powered microdebrider as a simple polypectomy device in the outpatient clinic setting.

Patients and methods

The vacuum-powered microdebrider is a disposable microdebrider consisting of a body containing the power

unit, a malleable shaft, a mucosa-sparing debrider blade, a suction port and an irrigation tube (Fig. 1A, B). Five to 10 minutes prior to the procedure, patients are anesthetized with topical 4% topical xylocaine and 0.05% oxymetazoline. The vacuum-powered microdebrider is then set up by connecting the clinic suction tube to the suction port of the device. Ten milliliters of normal saline is drawn up into a syringe and connected to the irrigation tube of the device. The irrigation tube is primed with normal saline and another 10 mL of normal saline is drawn into the syringe. The patient is then draped with a towel and disposable drape. The syringe (containing the irrigation fluid) can often be placed on the patient's lap or on the ear, nose, and throat (ENT) chair, enabling the surgeon to operate without an assistant. The suction machine is turned on and the surgeon is ready to begin the polypectomy using the microdebrider (Fig. 2). Upon completion of the

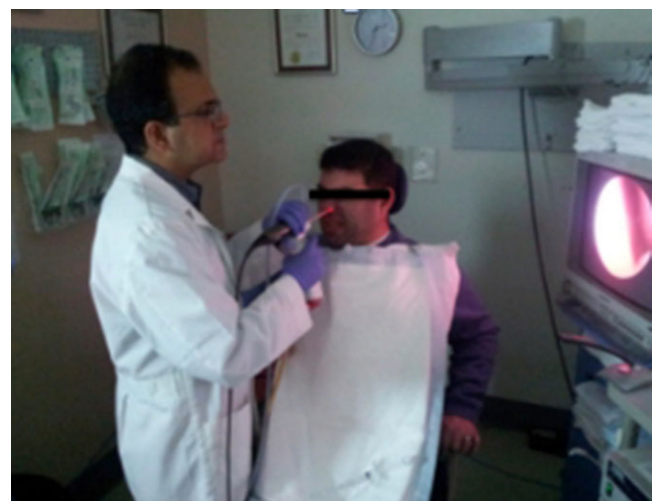

FIGURE 2. A vacuum-powered polypectomy performed in the outpatient setting.

procedure, the entire device is disposed into the sharps container.

At St Paul's Sinus Centre, all office polypectomies with the vacuum-powered microdebrider were performed by the senior author (ARJ). Prior to the procedure, patients were required to complete the 22-item Sino-Nasal Outcome Test (SNOT-22). Upon completion of the procedure, questionnaires pertaining to the efficacy, safety, and patient tolerability of the vacuum-powered microdebrider were completed by both the patients and the surgeon. The clinical charts of these patients who had the polypectomy performed between January 2012 and February 2013 were retrospectively reviewed. This study received ethics approval from the Institutional Review Board of Providence Health, Vancouver, Canada. The following clinical data were collected:

1. Patient demographics (age, sex);
2. History of previous treatments (previous oral or topical corticosteroids, FESS, and office polypectomy);
3. Indication for office polypectomy (recurrent polyposis, failed medical treatment, or awaiting surgery);
4. Operative details (time of procedure, patient comfort, extent of bleeding, consistency of polyps, and incidence of device failure);
5. Clinical outcomes postpolypectomy (using the SNOT-22 and documentation of grade of polyps prepolypectomy and postpolypectomy); and
6. Presence of complications (postprocedure persistent bleeding, injuries to middle turbinate, nasal septum, Eustachian tube, nasopharynx, orbit, and skull base).

Patient comfort was evaluated postprocedure on a 4-point scale (1 = poor, 2 = fair, 3 = good, 4 = excellent). Nasal polyp grade was evaluated with a 4-point scoring system (0 = none, 1 = in middle meatus [MM] only, 2 = below MM, 3 = total obstruction). Total SNOT-22 scores and nasal obstruction (measured on a 5-point scale: 0 = no problem, 1 = very mild, 2 = mild or slight, 3 = moderate, 4 = severe, 5 = as bad as could be) were also compared for significant differences. A type I error level of 5% ($\alpha = 0.05$) was used to test for significance. We defined a successful polypectomy as one that resulted in a postpolypectomy nasal polyp grade of at least 1 (out of 3) for middle meatal polyps, less than one-third of remnant polyps in sphenoethmoidal recess polyps, and no visible polyps seen in the middle meatus for antrochoanal polyps.

At the end of the polypectomy, all blood clots in the nasal cavities and nasopharynx were suctioned out. Following this, topical 4% xylocaine and 0.05% oxymetazoline spray were applied and patients were observed in the clinic. Bleeding was considered "light" when hemostasis was achieved after only 1 nasal suctioning and application of topical vasoconstrictor postprocedure and within 10 minutes of observation in the clinic; "moderate" when hemostasis was achieved after a second nasal suctioning and application of topical vasoconstrictor or after 10 to

TABLE 1. Subject characteristics*

Subject variables (n = 68)	
Age (years)	49 ± 13
Males	34 (50)
CRSwNP	37 (54)
AFRS	31 (46)
Samter's triad	2 (3)
Previous FESS	50 (74)
Previous polypectomy	22 (32)

*Values are n (%) or mean ± standard deviation.

AFRS = allergic fungal rhinosinusitis; CRSwNP = chronic rhinosinusitis with nasal polyposis; FESS = functional endoscopic sinus surgery.

30 minutes of observation in the clinic; and "severe" when hemostasis was achieved after 3 or more nasal suctioning and application of topical vasoconstrictor, after more than 30 minutes of observation in the clinic, or if nasal packing or hospital admission was required. Paired Student *t* test (2-tailed) was performed to evaluate if the change in the clinical outcomes postpolypectomy were statistically significant.

Results

A total of 68 patients received office-based polypectomy with the vacuum-powered microdebrider, with a mean age of 49 years. There was an equal distribution of males and females (Table 1). Fifty-three patients (78%) had previously received FESS and 15 (22%) subjects were primary cases presently on the waiting list for surgery. Twenty-one patients (31%) had previously received both FESS and an office-based polypectomy using the traditional electric-powered microdebrider. These interventions had occurred on a mean of 4.8 (range, 0.25–12) years and 27.5 (range, 2–98) months, respectively, prior to receiving the evaluated intervention. Office polypectomies were selected for these patients because 53 (78%) had recurrent polyps refractory to medical and/or surgical treatment. A total of 54 (79%) patients reported prior use of nasal steroid sprays and 25 (37%) reported use of oral steroids. Patients who had not used nasal steroid sprays previously were started on topical budesonide (Pulmicort Respules; 2 mL of 0.5 mg/mL) administered in the Mygind position using a Mucosal Atomization Device (MAD; Wolfe Tory Medical, Inc, Salt Lake City, UT) immediately after office polypectomy. These patients had their polypectomies performed during their first clinic consult to provide immediate relief of nasal obstruction and to allow access of topical nasal steroid into the sinus cavities.

Of all polypectomies with the vacuum-powered microdebrider, 59 (87%) were successfully completed. The remaining 9 (13%) polypectomies were unsuccessful. Unsuccessful

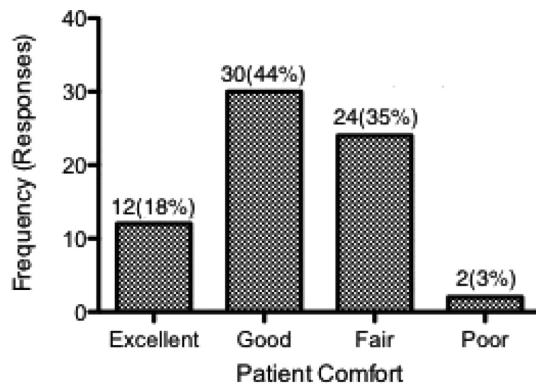


FIGURE 3. Patient comfort level during the procedure.

procedures were attributed to fibrous polyps that could not be sufficiently resected by the device ($n = 7$; 78%), mechanical failure ($n = 1$; 11%), and a deviated nasal septum that prevented access ($n = 1$; 11%). No adverse reactions or complications were encountered.

Patients presented with a mean prepolypectomy grade of 2.2 ± 0.8 on the left and 2.4 ± 0.7 on the right. The resected polyps were nonfibrous in 56 patients (82%) and fibrous in 12 patients (18%). The consistency of the polyps was evaluated by the procedurist (senior author). Resections were completed in a mean of 3 minutes per side. Resection primarily occurred within the ethmoid sinus (45%) and nasal cavities (36%). There were 6 (9%) polyps resected within the sphenoid recess and 3 (4%) antrochoanal polyps originating from the maxillary sinus. The majority of patients (44%) reported “good” comfort level during the procedure (Fig. 3). Bleeding was “light” in most cases (Fig. 4).

Postprocedure, polyps were reduced to a mean grade of 0.7 ± 0.5 on the left nasal cavity and 0.7 ± 0.5 on the right nasal cavity (Fig. 5). Paired Student *t* test comparing nasal polyp score indicated a significant difference between preprocedure and postprocedure grade for left and right sides, respectively ($p < 0.001$; 95% confidence interval [CI], 1.3–1.6; $p < 0.001$; 95% CI, 1.4–1.8) (Table 2, Fig. 5). Patients

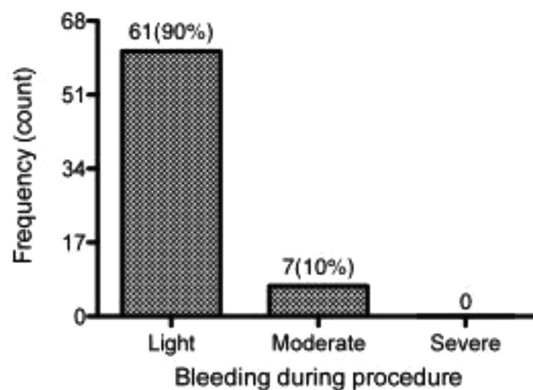


FIGURE 4. Severity of bleeding during and immediately after the procedure.

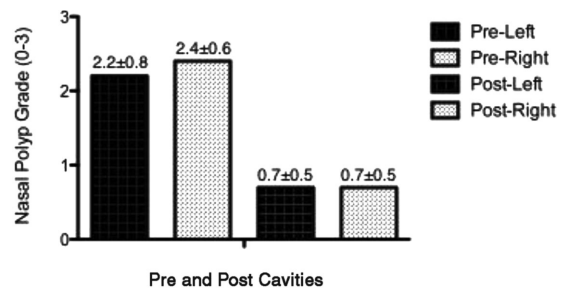


FIGURE 5. Pre vs. post polypectomy grade of nasal polyp.

reported reduced nasal obstruction (4.0 ± 1.2 vs 2.3 ± 1.7) when comparing preprocedure and postprocedure responses (Fig. 6).

Discussion

The introduction of nasendoscopy in the United States in the 1980s, combined with the ability to image the paranasal sinuses with computed tomography (CT) scan have revolutionized the surgical management of sinus disease.⁷ The next most significant technological advancement in sinus surgery after that was probably the advent of powered instruments, also known as microdebriders or soft-tissue shavers.⁷ The microdebrider was derived from modifications of arthroscopic instruments and popularized by Setliff in the 1990s.⁹ It is currently an essential and a standard instrument in the FESS set of most rhinologists. The suction aspect of the microdebrider allows not only soft tissue to be suctioned into the microdebrider for precise resection but also removal of blood and debris from the surgical field to provide good surgical field visualization. Microdebriders have proven effective in the removal of polyps in CRS^{9,10} and antrochoanal polyps,¹¹ reduction of

TABLE 2. Procedural details*

Areas performed (n = 119 areas)	Frequency (%)
Nasal	43 (36%)
Ethmoid	53 (45%)
Sphenoid	8 (7%)
Maxillary	9 (8%)
Frontal	6 (4%)
Consistency (n = 68)	Frequency (%)
Fibrous	12 (18%)
Nonfibrous	56 (82%)
Time (minutes)	Mean (Range)
Left	3.0 (1.6–10.0)
Right	3.0 (2.0–10.0)

*Values are n (%) or mean (range).

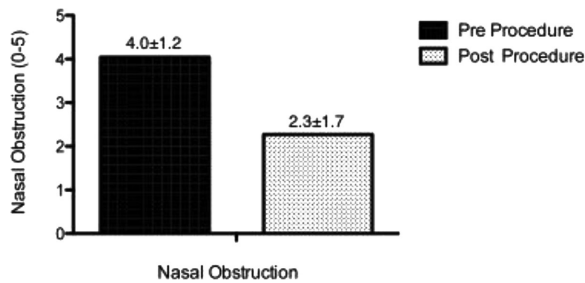


FIGURE 6. Pre vs. post polypectomy nasal obstruction.

inferior turbinate,^{12,13} and repair of choanal atresia.¹⁴ The handpiece of the microdebrider also accommodates various angled burrs, making it a very versatile instrument. The drill function of the microdebrider can be used in rhinoplasty (powered carbide rasp drill),⁷ dacryocystorhinostomy, modified Lothrop procedure, resection of tumors (eg, burring of tumor base), and in skull-base surgery (eg, leak site preparation in cerebrospinal fluid [CSF] leak).

As microdebriders are electric-powered, and they have high oscillating speeds and sharp cutting capabilities for precise soft tissue removal. However, these features, coupled with the continuous suction of the microdebrider, also render them potentially very hazardous instruments. A stroke of the rotating blade of the microdebrider can easily cut through the paper-thin lateral lamina of the cribriform plate and lamina papyracea. Once the bony walls are breached, critical soft-tissue structures such as dura, brain, and orbital contents can easily be aspirated and debrided by the powerful microdebrider. If and when this happens, the soft-tissue trauma is more extensive than iatrogenic injuries from the use of traditional non-powered cutting or grabbing FESS instruments. Use of powered instrumentation resulting in large dural defects with subsequent CSF leak and removal of underlying brain or orbital fat and muscles have been reported.¹⁵⁻¹⁸

Although electric-powered microdebriders have been used in the outpatient setting, there are several limitations that preclude them from being an ideal office tool. First, the setting up of the instrument is cumbersome. An electric-powered microdebrider requires a power console, an electric power point, a long irrigation tube, a saline bag for irrigation, a suction system, and often an assistant to wheel in the power console and set up the device. On the other hand, the vacuum-powered microdebrider is ready to be used once it is unboxed and the suction and a syringe containing normal saline are attached to it. The setup of an “out the box” device is less time consuming, with the device up and ready in less than a minute. The setup of the vacuum-powered microdebrider is also less bulky, with the absence of an electric power console. The less tedious and bulky setup of the vacuum-powered microdebrider often allows the surgeon to operate the device without an assistant.

Second, the electric-powered microdebrider is not disposable. The microdebrider blade is disposed of after each

use but the handpiece has to be sterilized. The downtime required for sterilization of the unit limits the number of office polypectomies in each clinic session. At St Paul’s Sinus Centre, each electric-powered handpiece can be used once per clinic session. As the vacuum-powered microdebrider is completely disposable, multiple polypectomies can be scheduled in a clinic session. The efficiency of the vacuum-powered microdebrider allows many patients requiring office polypectomies to be treated. After each use, the entire vacuum-powered microdebrider unit is disposed of into the sharps bin. The pricing of the vacuum-powered microdebrider has not been confirmed but is estimated to be comparable to an electric-powered microdebrider blade. However, taking into account the cost of and downtime for sterilization, the electric-powered microdebrider is expected to be less efficient as an office tool.

Third, the blade of the microdebrider in an electric-powered microdebrider is rigid. There are various individual angled blades available for the electric-powered microdebrider but using each different angled blade to access difficult areas in the sinuses will incur additional cost. In contrast, the vacuum-powered microdebrider has a malleable debrider tip that allows customization of the angle of the blade shaft to the requirement and satisfaction of the surgeon.

Finally, an electric-powered microdebrider lacks a storage container to collect soft tissue that has been debrided. The vacuum-powered microdebrider has a built-in storage container that traps the debrided polyps or soft tissue. This provides the surgeon an option for sending the trapped tissue for histological assessment should there be any suspicion of a tumor. Apart from that, trapped tissues and purulent material in the storage container can also be sent off for bacterial or fungal cultures if there is clinical evidence of an infection. This allows a culture-directed application of systemic or topical antibiotics to treat the infection.


Our case series showed that the vacuum-powered microdebrider was an effective device with a successful polypectomy rate of 87%. Clinically, patients showed a 43% improvement in nasal obstruction immediately postpolypectomy. Although patients completed prepolypectomy and postpolypectomy SNOT-22 score questionnaires, we compared only the prepolypectomy and postpolypectomy obstruction scores because the rest of the symptoms in the SNOT-22 score may not be alleviated immediately. The procedure was tolerable in the office setting; 97% of patients reported a comfort level of “fair” to “excellent.” It was also a safe device, with no significant bleeding encountered during or after the procedure. Hemostasis was achieved in all patients with postprocedure topical xylocaine and oxymetazoline. There was also no reported trauma on adjacent structures such as the middle turbinate, septum, Eustachian tube, nasopharynx, or any orbital and intracranial complications.

There were a few disadvantages of the vacuum-powered microdebrider. As the unit is dependent on vacuum power,

a weak suction system in the office will affect the power and efficacy of the device. The lower power output of the vacuum-powered microdebrider compared to an electric-powered also posed difficulties in resection of fibrous polyps. However, the reduced power output may also be a safety feature because the reduced cutting capability probably reduces the likelihood of orbital or intracranial penetration or violation. As with the electric-powered microdebrider, a complete office polypectomy can be hindered by anatomical anomalies such as a severely deviated nasal septum or a paradoxical middle turbinate. One of the limitations of this study was the absence or documentation of long-term symptom scores and polyp grades postpolypectomy. In addition, there was an inadequate follow-up period to allow detection of recurrent polyps; however, none of the early patients have been taken to the operating room for further surgery. There was also no direct comparison of the device to the current gold standard for office polypectomy, which is the electric-powered microdebrider. A study

of such nature is under review and consideration at our institution.

Conclusion

We present a case series of a new, novel, vacuum-based microdebrider for the outpatient clinic setting that has proven to be effective, safe, and tolerable. Future prospective single-blind studies comparing the efficacy and safety of a vacuum-powered microdebrider vs that of an electric-powered microdebrider to confirm the results of this study will be anticipated. 

Acknowledgments

We sincerely thank Rachele Dar Santos, BSc, CCRP, for her support and guidance in the process of obtaining ethics approval. We also thank Simon Zhou and Nadia Makan for their assistance in data collection. The vacuum-powered microdebriders used in this study were supplied by Laurimed LLC, Redwood City, CA.

References

- Desrosiers M, Evans GA, Keith PK, et al. Canadian clinical practice guidelines for acute and chronic rhinosinusitis. *J Otolaryngol Head Neck Surg.* 2011;40:S99-S193.
- Chen Y, Dales R, Lin M. The epidemiology of chronic rhinosinusitis in Canadians. *Laryngoscope.* 2003;113:1199-1205.
- Dykewicz MS, Hamilos DL. Rhinitis and sinusitis. *J Allergy Clin Immunol.* 2010;125(2 Suppl 2):S103-S115.
- Deal T, Kountakis S. Significance of nasal polyps in chronic rhinosinusitis: symptoms and surgical outcomes. *Laryngoscope.* 2004;114:1932-1935.
- Bonfils P. Medical treatment of naso-sinus polyposis: a prospective study of 181 patients. *Ann Otol Rhinol Laryngol.* 1998;115:202-214.
- Becker SS. Surgical management of polyps in the treatment of nasal airway obstruction. *Otolaryngol Clin North Am.* 2009;42:377-385.
- Hackman TG, Ferguson BJ. Powered instrumentation and tissue effects in the nose and paranasal sinuses. *Curr Opin Otolaryngol Head Neck Surg.* 2005;13:22-26.
- Becker DG. Powered instrumentation in surgery of the nose and paranasal sinuses. *Curr Opin Otolaryngol Head Neck Surg.* 2000;8:18-21.
- Setliff RC 3rd. The hummer: a remedy for apprehension in functional endoscopic sinus surgery. *Otolaryngol Clin North Am.* 1996;29:95-104.
- Becker DG. Sinusitis. *J Long Term Eff Med Implants.* 2003;13:175-194.
- Gendeh BS, Long YT, Misiran K. Antrochoanal polyps: clinical presentation and the role of powered endoscopic polypectomy. *Asian J Surg.* 2004;27:22-25.
- Yanez C. New technique for turbinate reduction in chronic hypertrophic rhinitis, intratubinate stroma removal using the microdebrider. *Oper Tech Otolaryngol Head Neck Surg.* 1998;9:135-137.
- Friedman M, Tanyeri H, Lim J, Landsberg R, Caldarelli D. A safe, alternative technique for inferior turbinate reduction. *Laryngoscope.* 1999;109:1834-1837.
- Rombaux P, de Toef C, Hamoir M, Eloy P, Bertrand B, Veykemans F. Transnasal repair of unilateral choanal atresia. *Rhinology.* 2003;41:31-36.
- Graham S, Nerad J. Orbital complications in endoscopic sinus surgery using powered instrumentation. *Laryngoscope.* 2003;113:874-878.
- May M, Levine HL, Mester SJ, Schaitkin B. Complications of endoscopic sinus surgery: analysis of 2108 patients- incidence and prevention. *Laryngoscope.* 1994;104:1080-1083.
- Church CA, Chiu AG, Vaughan WC. Endoscopic repair of large skull base defects after powered sinus surgery. *Otolaryngol Head Neck Surg.* 2003;129:204-209.
- Bhatti MT, Giannoni CM, Raynor E, Monshizadeh R, Levine LM. Ocular motility complications after endoscopic sinus surgery with powered cutting instruments. *Otolaryngol Head Neck Surg.* 2001;125:501-509.